

# CASE REPORT - ANIRIDIA LENS WITH MANUAL SUTURELESS MEDIUM INCISION CATARACT SURGERY – BIG SIZE, BIG SURPRISE

**A Case Study by Dr.Jasdeep Singh Sandhu, India**  
*(M.S. Ophthalmology, PG Up-gradation Student of Texila American University)*  
*Email: sandhujasdeepsingh@yahoo.co.in*

## ABSTRACT

Penetrating ocular trauma frequently causes combined lens and iris tissue injury resulting in traumatic cataract, ectopia lentis, corneal irregularities, traumatic aniridia or irideremia which can be complete or partial, hypoplasia of the iris and loss of iris diaphragm function. The management of patients with co-existing traumatic iris deficiencies and cataract is often challenging due to its heterogeneity, complexity and various associated ocular pathologies. The chief complaints may include photophobia, cosmetic defect, impaired vision and depth of focus. The current various technical options for the treatment of aniridia include iris diaphragm lenses, segmental prosthetic iris devices, flexible iris prosthesis and tinted or painted contact lens /intraocular lens.

We report a case of 44 year old male operated for coexisting traumatic cataract and aniridia by manual sutureless medium incision cataract surgery (MSMICS) and aniridia intraocular lens implantation.

## Case Report:

A 44 year old male soldier presented in the outpatient department with complaints of decreased vision in right eye for 2 ¼ years following a roadside accident. He had undergone primary repair of corneo-scleral perforation and hyphaema drainage elsewhere immediate to trauma.

## Examination Findings:

	<b>Right Eye</b>	<b>Left Eye</b>
Vision	PL+ PR+ (all quadrants)	6/6P
Pup. Reflexes	Normal-direct, consensual	Normal-direct, consensual
Intraocular Pressure:	Normal (Applanation)	Normal (Applanation)
Slit lamp examination:	Corneal scar with loose 10-0 nylon sutures in situ. Aniridia and total cataract with supero-temporal subluxation due to inferior zonular dihisence	Normal
Fundus details	Not visualized	Normal
B –Scan(done elsewhere)	Normal	Normal
VER(done elsewhere)	Normal	Normal

## **METHOD**

He was advised cataract extraction with aniridia intraocular lens implantation for the right eye and an informed consent was obtained. Under peribulbar anesthesia MSMICS was performed. A 10 mm sclera-corneal tunnel incision was made superiorly. A large continuous curvilinear capsulorhexis was performed and lens nucleus removed with visco-expression. The continuous curvilinear capsulorhexis was extended temporally to accommodate the large aniridia intraocular lens. The aniridia intraocular lens was placed with inferior optic and both haptics in capsular bag (3 and 9 clock hours) while the superior optic was sulcus placed. Air was injected in A.C. and wound hydrated at end of surgery. No sutures were used to close the incision. Routine post-operative drug regimen was adhered to.

## **RESULT**

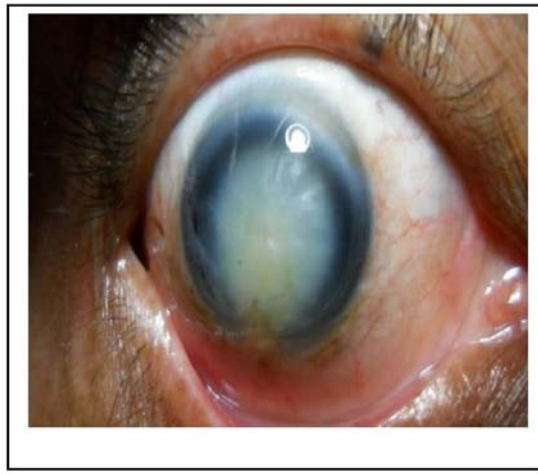Both the immediate and delayed post operative period was uneventful. There was no photophobia or glare experienced by the patient postoperatively. The intraocular lens was well-centered without any tilt. The best corrected visual acuity on days 3, 10 and 45 postoperatively were 6/6P, 6/6, and 6/5 respectively. The patient and his family were satisfied with the cosmesis obtained for the eye.

## **CONCLUSION**

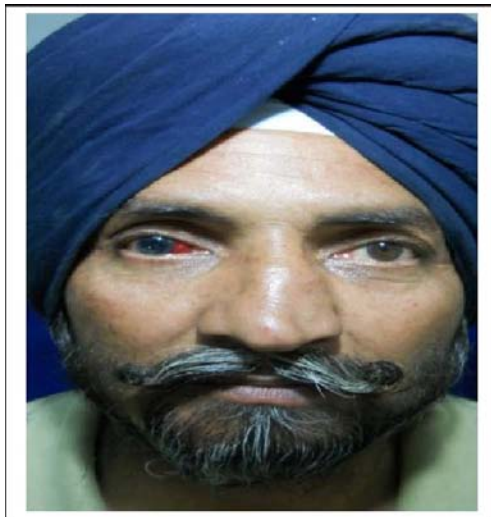
The restoration of normal vision and good cosmetic results after an injury as severe as leading to complete aniridia and traumatic cataract although not unique is surprising. The aniridia intraocular lens implant seems to be a beneficial therapeutic option in achieving mechanical, physiologic, optical and cosmetic success in eyes with coexisting aniridia and cataract. The successful incorporation of the skills of manual sutureless cataract surgery and the aniridia IOL implantation can become the procedure of choice for similar situations.



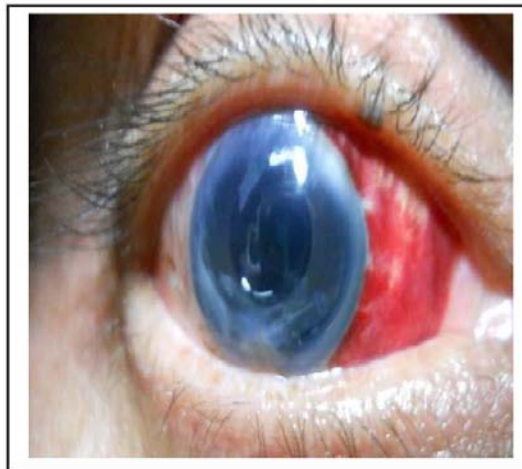
Picture 1: Pre-operative



Picture 2: Pre-operative showing total aniridia and dense traumatic cataract



Picture 3: Ten days post-operative



Picture 4: Ten days post-operative showing well centered aniridia