

ROLE OF ULTRASOUND IN TESTICULAR AND SCROTAL TRAUMA

A Case Study by Dr Vikash Kumar Bhojasiya, India
(MBBS, MD Radiology Student of Texila American University)
Email: bhojasiyavikas@yahoo.co.in

SOURCE

Bhatt S, Dogra V S ,2008, 'Role of Ultrasound in Testicular and Scrotal Trauma, **RadioGraphics 2008**; 28:1617–1629 • Published online 10.1148/rg.286085507
<http://radiographics.rsna.org/content/28/6/1617.full.pdf+html>

ABSTRACT

Testis is the superficial structure and scrotum has thin skin and subcutaneous tissue. This makes the evaluation of the testis by ultrasound very accurate and effective. However, high frequency to be used for evaluation of such structures to get best resolution. This article was mainly describing the role of the high frequency ultrasound for testicular trauma. This can find out and depict very nicely even the minute quantity of fluid (less than 1cc) .It can pick a tiny lesion as small as 2-3mm.Hence any traumatic rupture, hemorrhage, collection ,contusion, parenchymal changes can be diagnosed with 100% accuracy. The use of doppler along with the imaging increases its sensitivity, particularly in finding out the infarctions and mass lesions. Ultrasound not only has role in diagnosis, but also helps in management of such cases to evaluate the response of the treatment

INTRODUCTION

This review critically analyze the article **Role of Ultrasound in Testicular and Scrotal Traum, RadioGraphics 2008**; 28:1617–1629 • Published online 10.1148/rg.286085507. This is a review of each and every step by step research done of particular topic to evaluated the role of ultrasound. From the beginning it reviews the abstract to the conclusion in end.During this process we had particular directions and criteria for evaluating the efficacy and credibility of the article.After reading the article, we will commenting the pitfalls and drawbacks as well. It has put sincere efforts in the evaluation of the accuracy and authority of the article. Overall the article was well written, clear and relevant.

REVIEW OF LITERATURE

Testicular trauma is the third most common cause of acute scrotal pain, and high-frequency ultrasonography (US) with a linear-array transducer is the modality of first choice for the

evaluation of testicular trauma . The need for US is further underscored because the clinical manifestations are not always correlative to or reliably indicative of testicular injuries. US findings may vary from a small hematocele requiring conservative management to a testicular rupture demanding immediate surgical intervention. US therefore is helpful in the triage of patients for surgical or nonsurgical management.

Testicular torsion was first described by Delasiauve in 1840. It was not widely regarded as a significant problem until 1907, when Rigby and Russell published their work on torsion of the testis in *Lancet*. The first description of neonatal torsion was described by Taylor in 1897. Subsequently, Colt reported torsion of the appendix testis in 1922.

ANATOMY OF THE SCROTUM AND TESTES

Each hemiscrotum contains a testis with its coverings, epididymis, and spermatic cord. The tunica albuginea, with its great tensile strength, plays a significant role in protecting the testis from trauma. It can sustain a force of as much as 50 kg without rupturing.

US TECHNIQUE

Scrotal US is performed with the patient lying in a supine position and with the scrotum supported by a towel placed between the thighs. The use of a 7–14-MHz high-frequency linear-array transducer is preferred. After trauma, the scrotum is often tender to the touch, which makes scanning difficult. An attempt should be made to evaluate both testes and epididymides in their entirety and to identify any extratesticular collections.

MECHANISMS OF INJURY

Sporting activities account for more than half of all cases of testicular injury, and motor vehicle accidents account for another 9%–17% of testicular injuries. The three main categories of injury to the scrotum are blunt injuries, penetrating injuries, and iatrogenic injuries.

US FINDINGS

- ☞ Testicular Rupture - *Disruption of the Tunica Albuginea; Contour Abnormality of the Testis; Absence of Vascularity in the Testis Heterogeneous Echotexture of the Testis.*—
- ☞ Testicular Fracture
- ☞ Testicular Dislocation
- ☞ Testicular Torsion
- ☞ Intratesticular Hematoma
- ☞ Intratesticular Pseudoaneurysm
- ☞ Penetrating Injury

- ☞ Extratesticular Injuries; *Hematoma (Hematocele)*; *Scrotal Wall Hematoma*; *Traumatic Epididymitis*
- ☞ Epididymal Fracture and Rupture; *Spermatic Cord Hematoma*
- ☞ Rare Testicular and Scrotal Injuries

ARTICLE SUMMARY

The purpose of this article is to get complete knowledge and understanding of all kind of injuries in testis and extratesticular area. The fact that ultrasound has profound role in diagnosis and management acute scrotal pain and evaluation of the traumatic scrotum.

High-frequency US performed with a linear array transducer helps identify both the normal tunica albuginea and its rupture with greater ease . The amount of swelling and ecchymosis may vary, and the degree of hematoma does not necessarily correlate with the severity of testicular injury. The absence of external signs does not entirely rule out a testicular rupture; a contusion without a fracture of the tunica albuginea may be accompanied by significant bleeding that requires surgical intervention. Early surgical exploration is important in patients with negative US findings of testicular injury when there is a high risk or a high degree of suspicion—for example, in patients who have undergone trauma involving high-energy transfer mechanisms.

ARTICLE STRUCTURE

The article was introduced with an abstract, which provided the base developed by the article as well as a brief overview of main points. Then it gives information about the anatomy of scrotum and testes, followed by ultrasound technique. The way of describing the mechanism of injury gives in depth knowledge of the pathology. Each ultrasound findings were described indetail which includes testicular rupture to torsion and various other findings. The article also mentions and gives importance the extratesticular findings and some rare findings which completes the article The summary was made at the end of the article; although short but it made a complete sense and solves the objective of the article. References were cited in-text and set out clearly in the literature cited section.

ARTICLE CRITIQUE

Authority

RadioGraphics, a bimonthly journal devoted to continuing medical education in radiology, is owned and published by the **Radiological Society of North America, Inc (RSNA)**. This journal being freely accessible all over the world in internet had made a strong base of study for all medical faculty. The journal is abstracted and indexed in [MEDLINE/PubMed](#).

The author's credibility was established in a number of ways. These included their MD; the fact that the article was a peer reviewed article; the fact that the article is cited by many other similar articles. Author is an academician and presented many articles in various international journals. The fact that they are recipient of a *Certificate of Merit award* for an education exhibit at the 2007 RSNA Annual Meeting.

Accuracy

The information presented in the article was very delicately linked to many referenced, wherein required. Author has put forwards the pictures taken from his own study and it clearly demonstrates the accuracy of diagnosis. Each picture was appropriately labelled and informed about the details. It gives a detailed information about the imaging findings for every lesion in the traumatic testicular or extratesticular region.

Currency

The article was received in February 4, 2008; revision requested March 16 and received March 31; accepted April 7. It was published online in 2008 October. The research it describes was current and the article cites up-to-date references in the body of the text (ranging from 1990-2008). Therefore the article is current.

Relevance

This article gives a very good information about the testicular and extratesticular findings. All the pictures are very clear and self explanatory. Title below the images clearly mentions the relevance. All the headings and subheadings are nicely written. Anatomy of the testis was also very useful data for all. Hence the article is one of the best informative source for all the medical fraternity

Objectivity

The objective of this article was to give up to date knowledge about various scrotal pathologies occurring as a result of trauma. The article has described each and every topic in a very clear manner and illustrate the images accordingly. The information conveyed is well supported with various research articles and reference was given at appropriate places. There was no evidence of bias. There was complete description of mechanism of injury to happen and cause scrotal pathologies. With the help of images and tables the objective of the article is fulfilled.

Stability

The article, with its source an academic journal on an academic data base is stable as a resource

ANALYSIS OF GRAPH/IMAGE/TABLE

The study had put a table and many images at appropriate places. The image quality was perfect to understand. The label was clearly mentioned in the images. All images are self explanatory. The table gives a spot summary of US findings and management of testicular and extratesticular Injuries from scrotal trauma.

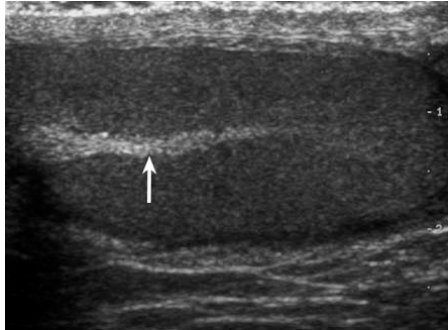


Figure 1 - Normal mediastinum testis. Longitudinal gray-scale US image of a normal testis shows a linear echogenic structure (arrow) along the long axis of the testis.

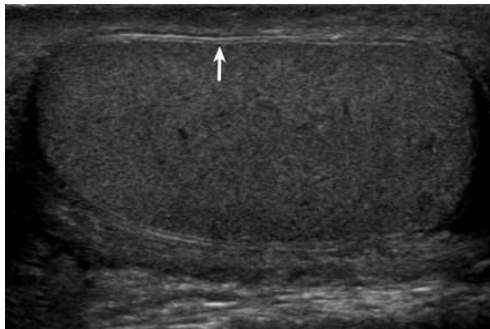


Figure 2 - Normal tunica albuginea. Longitudinal gray-scale US image of a normal testis depicts a thin echogenic line (arrow) around the testis

Recent Advances Related to the Topic

High frequency ultrasound with color doppler is the current modality of the investigation for all types of scrotal pathologies. However, CT or MRI can also be used for evaluation in the certain cases. Despite the high cost and limited availability, magnetic resonance imaging with the dynamic contrast-enhanced subtraction technique provides accurate information on morphology as well as blood flow. Infrared scrotal thermography increases accuracy in the diagnosis of varicocele.

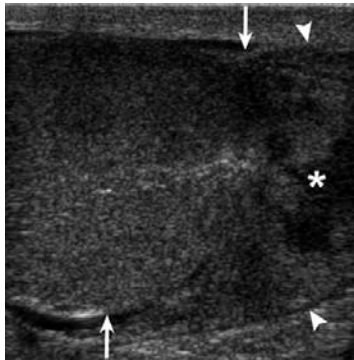

Figure 3 - Longitudinal gray-scale US image of the right testis in a patient with scrotal trauma shows localized disruption of the tunica albuginea (arrows) with associated contour abnormality (arrowheads) and heterogeneous echotexture of the testicular parenchyma

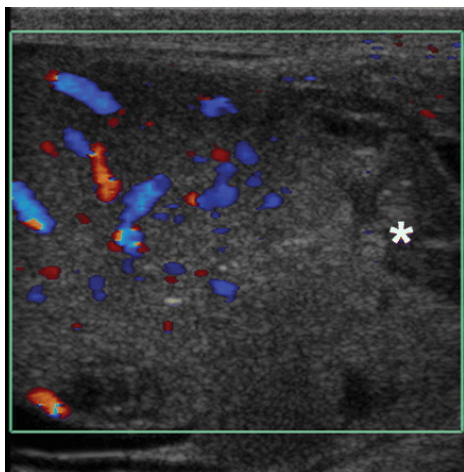


Figure 4 - Color Doppler US image depicts an absence of vascularity in the extruded lower pole of the testis. Surgical débridement of the inferior pole was performed with salvage of the uninjured part of the testis

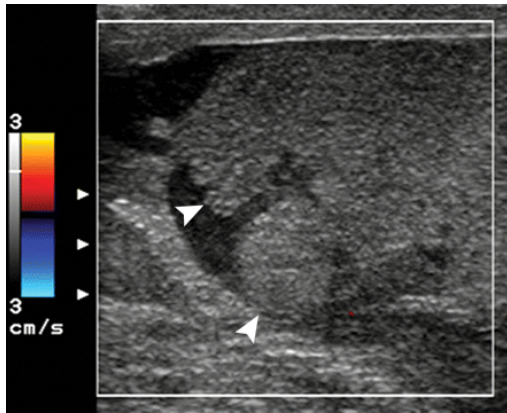


Figure 5 – Testicular rupture. Longitudinal color Doppler US image of the right testis in a patient with more severe scrotal trauma shows complete disruption of the tunica albuginea with testicular contour abnormality (arrowheads) and no vascularity. The contralateral testis (not shown) also was ruptured. A bilateral orchiectomy was performed.

CONCLUSION

This review has both summarized and critically reviewed article ‘**Role of Ultrasound in Testicular and Scrotal Trauma**’. The content, structure, strengths and limitations of the article were analyzed and critiqued. The article has contributed to the literature in terms of its valuable critique of current research study on severity of the acute scrotum due to trauma. Prognosis of acute scrotum can be depicted by ultrasound and doppler evaluation. Scrotal trauma calls for careful physical and imaging evaluations to determine the appropriate management of injuries. US is the modality of choice for imaging of scrotal trauma because it allows reliable identification of various testicular and extratesticular injuries. The management options, like the US findings, vary according to the type of injury. Testicular rupture, the most severe testicular injury, requires immediate surgical intervention to salvage the testis.

REFERENCES

- 1) Adigun, I., A., Kuranga, S., A., Abdulrahman, L., O (2002). Grinding Machine: Friend or Foe. *West Afr J Med*, 21, 338–340.
- 2) Altarac, S. Management of 53 Cases of Testicular Trauma (1994). *Eur Urol*, 25, 119–123.
- 3) Bhatt, S., Dogra, V., S (2007). Utility Of High Frequency Transducer Sonography in Scrotal Trauma. *Presented at the annual meeting of the American Institute of Ultrasound in Medicine, New York, NY, March 15–18.*

- 4) Bhatt, S., Ghazale, H., Dogra, V., S (2007). Sonographic Evaluation of Scrotal And Penile Trauma. *Ultrasound Clin*, 2, 45–56.
- 5) Blaivas, M., Brannam, L (2004). Testicular Ultrasound. *Emerg Med Clin North Am* 22, 723–748.
- 6) Bedir, S., Yildirim, I., Sumer, F., Tahmaz, L., Dayanc, M., Peker, A., F (2005). Testicular Dislocation As A Delayed Presentation of Scrotal Trauma. *J Trauma*, 58, 404–405.
- 7) Bromberg, W., Wong, C., Kurek, S., Salim, A (2003). Traumatic Bilateral Testicular Dislocation. *J Trauma*, 54, 1009–1011.
- 8) Buckley, J., C., McAninch, J., W (2006). Use Of Ultrasonography For The Diagnosis of Testicular Injuries In Blunt Scrotal Trauma. *J Urol* , 175, 175–178.
- 9) Cass, A., S., Ferrara, L., Wolpert, J., Lee, J (1988). Bilateral Testicular Injury From External Trauma. *J Urol*, 140, 1435–1436.
- 10) Cass, A., S., Luxenberg, M (1991). Testicular Injuries. *Urology*, 37 , 528–530.
- 11) Corrales, J., G., Corbel, L., Cipolla, B., et al (1993). Accuracy of Ultrasound Diagnosis After Blunt Testicular Trauma. *J Urol*, 150 , 1834–1836.
- 12) Cohen, H., L., Shapiro, M., L., Haller, J., O., Glassberg, K (1992). Sonography of Intrascrotal Hematomas Simulating Testicular Rupture in Adolescents. *Pediatr Radiol*, 22, 296–297.
- 13) Deurdulian, C., Mittelstaedt, C., A., Chong, W., K., Fielding, J., R (2007). US of Acute Scrotal Trauma: Optimal Technique, Imaging Findings, And Management. *Radio-Graphics*, 27, 357–369.
- 14) Dogra, V., S, Gottlieb, R., H, Oka, M., Rubens, D., J (2003). Sonography of the Scrotum. *Radiology*, 227, 18–36.
- 15) Dogra, V., Bhatt, S. Acute Painful Scrotum (2004). *Radiol Clin North Am*, 42, 349–363.
- 16) Guichard, G., El Ammari, J., Del Coro, C., et al. (2008). Accuracy of Ultrasonography in Diagnosis of Testicular Rupture After Blunt Scrotal Trauma. *Urology*, 71, 52–56.
- 17) Hayami, S., Ishigooka, M., Suzuki, Y., Sasagawa, I., Nakada, T., Mitobe, K (1996). Pathological Changes Of Traumatic Dislocated Test Is. *Urol Int*, 56, 129–132.
- 18) Haas, C., A., Brown, S., L., Spirnak, J., P (1999). Penile Fracture And Testicular Rupture. *World J Urol* 17, 101–106.

- 19) Ihama, Y., Fuke, C., Miyazaki, T (2007). A Two-Rider Motorcycle Accident Involving Injuries Around Groin Area in Both the Driver and The Passenger. *Leg Med (Tokyo)*, 9, 274–277.
- 20) Jeffrey, R., B., Laing, F., C., Hricak, H., McAninch, J., W. Sonography of Testicular Trauma (1983). *AJR Am J Roentgenol* 141, 993–995.
- 21) Kratzik, C., Hainz, A., Kuber, W., et al (1989). Has Ultrasound Influenced The Therapy Concept of Blunt Scrotal Trauma? *J Urol*, 142, 1243–1246.
- 22) Lupetin, A., R., King, W., 3rd, Rich, P., J., Lederman, R., B (1983). The Traumatized Scrotum: Ultrasound Evaluation. *Radiology*, 148, 203–207.
- 23) Lee, J., Y., Cass, A., S., Streitz, J., M (1992). Traumatic Dislocation of Testes And Bladder Rupture. *Urology*, 40, 506–508.
- 24) Lujan, Marco, S., Budia, Alba, A., Bango, Garcia, V., Ramirez, Backhaus, M., Delgado, Oliva, F., J., Jimenez, Cruz, J., F (2006). Traumatic Testicular Dislocation [in Spanish]. *Actas Urol Esp*, 30, 409–411.
- 25) Micallef, M., Ahmad, I., Ramesh, N., Hurley, M., McInerney, D (2001). Ultrasound Features of Blunt Testicular Injury. *Injury*, 32, 23–26.
- 26) Mulhall, J., P., Gabram, S., G., Jacobs, L., M (1995). Emergency Management of Blunt Testicular Trauma. *Acad Emerg Med*, 2, 639–643.
- 27) Muttarak, M., Thinyu, S., Lojanapiwat, B (2007). Clinics In Diagnostic Imaging (114): Rupture of the Right Testis. *Singapore Med J*, 48, 264–268.
- 28) Pepe, P., Panella, P., Pennisi, M., Aragona, F (2006). Does Color Doppler Sonography Improve the Clinical Assessment of Patients With Acute Scrotum? *Eur J Radiol*, 60, 120–124.
- 29) Ragheb, D., Higgins, J., L. (2002). Jr. Ultrasonography of The Scrotum: Technique, Anatomy, And Pathologic Entities. *J Ultrasound Med*, 2002 (21), 171–185.
- 30) Ridgway PF, Shah J, Darzi AW (2002). Male genital tract injuries after contemporary inguinal hernia repair. *BJU Int*, 90, 272–276.
- 31) Schwartz, S., L., Faerber, G., J (1994). Dislocation Of The Testis As a Delayed Presentation of Scrotal Trauma. *Urology*, 43, 743–745.
- 32) Taylor, E., W., Duffy, K., Lee, K., et al (2004). Surgical Site Infection After Groin Hernia Repair. *Br Surg*, 91, 105–111.

33) Wessells, H., Long, L (2006) . Penile And Genital Injuries. *Urol Clin North Am*, 33, 117–126.