

## Gynaecomastia and pseudo gynaecomastia

Article by Sreelatha Murugappan  
*PhD in Medicine by Research in Cosmetology, Texila American University*  
Email: murugappan.spm@gmail.com

### **Abstract**

*The common male problem, Gyanecomastia, is truly Pseudo gynaecomastia with only fatty tissue and minimal glandular tissue. The condition is a part of the co existing Obesity disorder and is rarely, a standalone entity. The treatment options shall include an approach to answer the issue of obesity as a whole, not rest contented with surgical removal of the enlarged breasts alone, as what is seen and what is treated is just a tip of the iceberg. Surgical removal of fatty tissue and extrication of glandular tissue by laser liposuction under Tumescant anaesthesia helps in avoiding the sub areolar incision.*

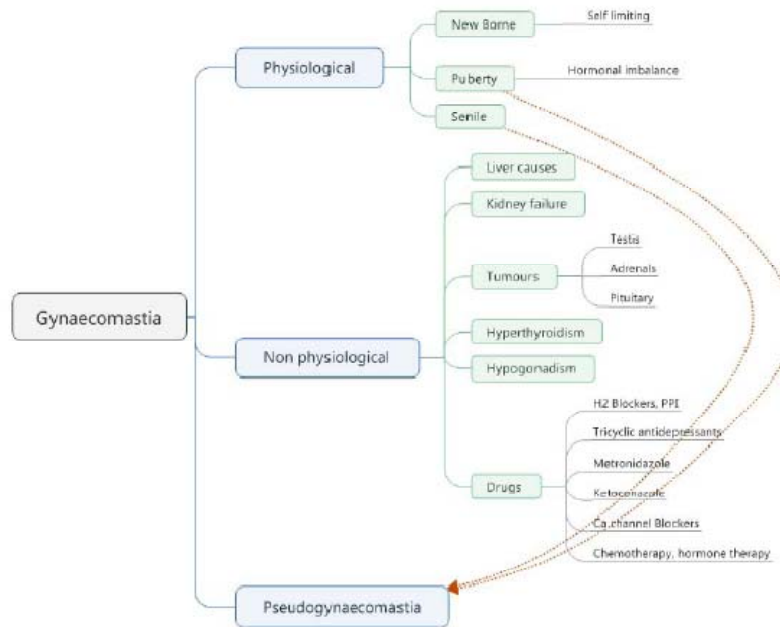
**Keywords:** *Gynaecomastia, laser liposuction, pseudogynaecomastia*

### **Introduction**

The common male problem in an Aesthetic clinic, Gyanecomastia, is truly Pseudo gynaecomastia with only fatty tissue and minimal glandular tissue. The condition is a part of the co existing Obesity disorder and is rarely, a standalone entity. The treatment options shall include an approach to answer the issue of obesity as a whole, not rest contented with surgical removal of the enlarged breasts alone. What is seen and what is treated is just a tip of the iceberg. Gynaecomastia, an innocuous condition that affects 35-70% of male population immediately after birth, during adolescence and old age is rarely brought to notice as the sufferer makes all attempts to hide it as the condition brings with it a sense of shame and pain in public places and mental suffering. Herein starts the search for the treatment. Medical and multifaceted surgical options evolved over centuries with the current opinion being fat removal by anyone form of liposuction and the gland removal by direct excision.

Gynaecomastia, is increased breast tissue in males composed of glandular and fatty tissue. Physiological gynaecomastia of puberty that normally regresses with age tend to stay back being sustained by the modern lifestyle changes. Processed foods and environmental pollution of air and water, the cosmetics used on the body like deo odorants, perfumes and toiletries, synthetics and chemicals have contributed to explosions of generalised obesity. With this generalised obesity, the tendency to hold back excess fat in the breast developed. This clearly shows the reason for higher incidence of (pseudo) Gynaecomastia of late. Hormonal imbalance due to reasons stated above, aggravate the situation. Gynaecomastia is part of the generalised obesity and it is more fat and little gland.

## Gynaecomastia variants



## Materials and methods

The study was conducted in 35 consecutive patients of gynaecomastia. They were in the age group 21-35 (n=33) and above 45 (n=2). Weight < 80 Kgs (n=8) and >80 kgs (n=27). Gynaecomastia Grade Gr2-3(n=33), Gr 1(n=1) and Sagging breast with lax skin (n=1). BMI Below 25 (n=1), 25-29.9 (n=5), above 30 (n=29). Ultrasonogram of all showed normal glands and did not show any glandular enlargement in any (max size=2.1 cm). Clinical examination showed the enlarged breast was fatty tissue and rarely glandular tissue was felt. The two persons above 45 years diagnosed as gynaecomastia had sagging breasts with laxity of skin and displacement of nipples far down below the normal. The sagging was found due to lax chest muscle and when the sag was pulled up, the lookalike of gynaecomastia' disappeared.

## Procedure

Under Tumescant Anaesthesia, with a 3 mm incision in the ant axillary line, 1470 nm laser (Alma LipoEZE) 600 micron fibre passed in radial directions across the breasts. The fibre was passed across the gland after the fat was removed and the gland fragmented with the heat. Large chunks of the gland that were not removed by suction were pulled out by fine forceps thro the same path. Tight strapping applied and patients reviewed after 2 days. 1 patient had bleeding that was arrested by inj haemocoagulase and compression. Post operatively, the patient had haematoma. The satisfaction rates as given by the patients were very good to excellent (n=26) and good and satisfied (n=9).

The need to reduce weight by increasing Basal Metabolic Rate and lifestyle changes to prevent recurrence or weight gain was reinforced into the minds. This included a change in dietary composition that avoided all processed foods of any kind and a change in exercise types of High Intensity Intervals and 3Dimensional exercise that could be performed over few seconds to minutes with long lasting effects and hormonal balance restoration. The results were evident by corresponding weight loss

## Conclusion

True Gynaecomastia that requires surgical treatment is not so uncommon. What is commonly believed to be gynaecomastia is truly Pseudo gynaecomastia with a co exiting

clinical picture of obesity, high BMI, sedentary life and wrong lifestyle. Surgical treatment by laser liposuction under Tumescant Anaesthesia gives very good results with high patient satisfaction and negligible post operative complications. Gland fragmented with laser can be extricated thro' same entry point without sub areolar incision.

## References

- [1.] Barros AC, Sampaio Mde C (2012). "Gynecomastia: physiopathology, evaluation and treatment". *Sao Paulo Medical Journal* **130** (3): 187–97. doi:10.1590/s1516-31802012000300009
- [2.] "Breast enlargement in males". *Medline Plus. US National Library of Medicine*. Retrieved 15 November 2015.
- [3.] Cordova A, Moschella F (2008). "Algorithm for clinical evaluation and surgical treatment of gynaecomastia". *J Plast Reconstr Aesthet Surg* **61** (1): 41–9. doi:10.1016/j.bjps.2007.09.033
- [4.] "Current concepts in gynaecomastia". *Surgeon* **7** (2): 114–19. doi:10.1016/s1479-666x(09)80026-7
- [5.] Deepinder F, Braunstein GD (2012). "Drug-induced gynecomastia: an evidence-based review.". *Expert opinion on drug safety* **11** (5): 779–795. doi:10.1517/14740338.2012.712109
- [6.] Erol S, Orhan E, Sevin A, Erdogan B. Trauma: a new pseudogynecomastia cause. *Aesth Plast Surg*.2010;34:404–405. doi: 10.1007/s00266-009-9435-8
- [7.] Erol S, Orhan E, Sevin A, Erdogan B. Trauma: a new pseudogynecomastia cause. *Aesth Plast Surg*.2010;34:404–405. doi: 10.1007/s00266-009-9435-8. [PubMed] [Cross Ref]
- [8.] Narula HS, Carlson HE (August 2014). "Gynaecomastia-pathophysiology, diagnosis and treatment". *Nat Rev Endocrinol* **10** (11): 684–698. doi:10.1038/nrendo.2014.139
- [9.] Rohrich RJ, Ha RY, Kenkel JM, Adams WP., Jr Classification and management of gynecomastia: defining the role of ultrasound-assisted liposuction. *Plast Reconstr Surg*. 2003;111:909–923. doi: 10.1097/01.PRS.0000042146.40379.25.
- [10.] Venkata Ratnam B. A new classification and treatment protocol for gynecomastia. *Aesth Surg J*.2009;29:26–31. doi: 10.1016/j.asj.2008.11.003
- [11.] Wollina, U; Goldman, A (June 2011). "Minimally invasive esthetic procedures of the male breast". *Journal of cosmetic dermatology* **10** (2): 150–155. doi:10.1111/j.1473-2165.2011.00548

## Author's profile:



Dr. Sreelatha Murugappan  
Cosmetic Laser Surgeon at Silkee Cosmetology Laser Research Institute, Chennai, India  
Specialising in body sculpting by laser liposuction methods.