

Actinomycosis with pericardio-pleural effusion and ascites. A Rare presentation

Article by Naresh Sen¹, Sonal Tanwar²

¹Anand Multispeciality Hospital, Beawar, Rajasthan (India)
Email id- drnaresh.sen@gmail.com

²Anand Multispeciality Hospital, Beawar, Rajasthan (India)
Email id- drsonalnaresh2011@gmail.com

Abstract

Background- Actinomycosis is an uncommon disease caused by *Actinomyces spp.*, Gram-positive, anaerobic or microaerobic bacteria that normally colonize the human mouth and GIT and genital tracts. Cardio-pulmonary actinomycosis with peritoneal involvement is a rare presentation.

Case report – A 29 years old female normotensive and euglycemic, smoker with poor oral hygiene was referred to us an outside hospital with complaints of right lower chest pain with severe shortness of breath and low grade fever last 4 hrs . On examination she showed dental caries, right chest bulging with diminished breath sounds, distended abdomen, raised WBC counts and normal ECG, Chest X-Ray showed right sided pleural effusion and bilateral opacities, pericardial effusion and ascites which were confirmed by 2D echo, CT chest & abdomen . Lab tests were negative for tuberculosis or malignancy. Finally she was diagnosed as an actinomycosis israelii based on culture and biopsy. She was treated with long course of appropriate antibiotics and fluid drainage.

Conclusion- Patients with actinomycosis require prolonged high doses of penicillin G or amoxicillin and other sensitive antibiotics and drainage. Early diagnosis will reduce the hospital stay or mortality in such kind of patients.

1. Introduction

Actinomycosis cases are found very uncommonly across the world with an incidence around 1 in 2,00,000 population. Generally they present with lesions of mouth, GIT and genitalia. It presents as cardiopulmonary or abdominal actinomycosis. Actinomycosis occurs due to actinomyces sp., actinomyces israelii or actinomyces odontolyticus which are gram positive, anaerobic or microaerophilic filamentous bacilli. Previously a few cases were reported with cardiac or pulmonary actinomycosis but we are reporting case of cardiopulmonary with abdominal actinomycosis with presenting with pericardial effusion, pleural effusion and Ascites which is perhaps the first reported case of this nature.

2. Case Report

A 29 years old female was admitted in emergency department with severe breathlessness, poor mental status and drowsiness, pulse rate 141 beats per minute, respiratory rate 37 /min, low grade fever and spo2 -66% . Immediately she was shifted to ICU at our medical centre.

Prior to her admission with us, she was admitted with history of acute abdominal pain, chest heaviness and 3 months history of amenorrhea and was suspected to have either small ill-defined ovarian mass or ectopic pregnancy. At surgery it looked like ovarian mass with pelvic and peritoneal fluid collection rather than ectopic pregnancy and the mass could be removed totally. Due to suspicion of tubercular or malignant etiology fluid sample and piece of tissue from the

mass were sent for culture and biopsy. On the same day of post operative procedure patient developed sudden severe breathlessness with referred to our medical centre.

In ICU she was put on oxygen, head-down position, IV fluids, inotropes and other supportive measures. On the examination she was in a confused state. The oral cavity was unhealthy with dental caries, pallor, leg edema, and abdominal distention, blood pressure - 98/48 mmHg, pulse-141 beats/min, jugular venous pressure of 7 cm, no pulsus paradoxus, no pericardial rub, muffled heart sounds, no murmur, right chest bulging with diminished breath sounds and no neurological deficit. Electrocardiogram showed low voltage otherwise normal ST-T changes and Chest x-ray revealed pleural effusion and pericardial effusion (figure-1A).

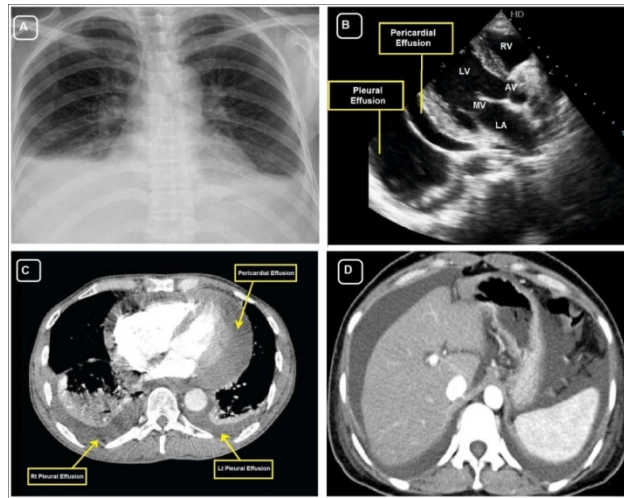


Figure-1. Chest x-ray revealed pleural effusion and pericardial effusion (figure-1A). which were confirmed by 2D echo (figure-1B) and CT chest (figure-1C), followed by CT abdomen (figure-1D) revealed ascites without any mass or lesion .

The same were confirmed by 2D echo (figure-1B) and CT chest (figure-1C), followed by CT abdomen (figure-1D) which revealed ascites without any mass lesion . Normal values for Adenosine deaminase ; ADA, ADA-2 and Gama-interferon and normal or cytology ruled out TB or malignancy. Culture showed branched elongated bacilli (figure-2A) and histopathological examination from the ovarian mass showed presence of chronic abscess with acute and chronic inflammation, surrounding granulation tissue and fibrosis (figure- 2B). A few characteristic filaments of organisms are noted which are PAS positive. No evidence of malignancy or granulomatous inflammation. Finally she was diagnosed as a case of actinomyces isroellii infection .

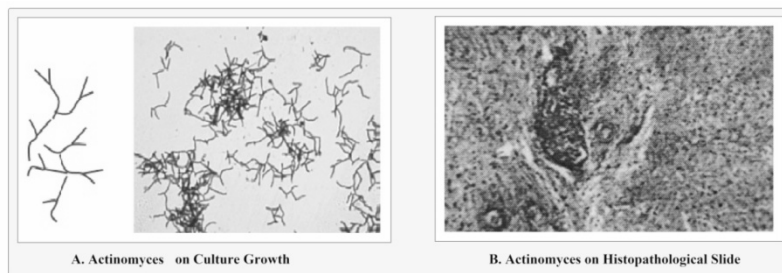


Figure 2. Culture showed branched elongated bacilli (figure-2A) and histopathological examination from the ovarian mass showed presence of chronic abscess with acute and chronic inflammation, surrounding granulation tissue and fibrosis (figure- 2B).

As per antibiotic sensitivity reports she was treated with *imipenam plus cilastatin* and amoxicillin plus clavulonic acid intravenously for 2 weeks with support of pericardial and pleural drain followed by oral amoxycilin-clav for next 6 weeks and other supportive therapies. No surgical interventions were required.

At 6 weeks follow-up she became asymptomatic and recovered radiologically as well(Fig.-3).

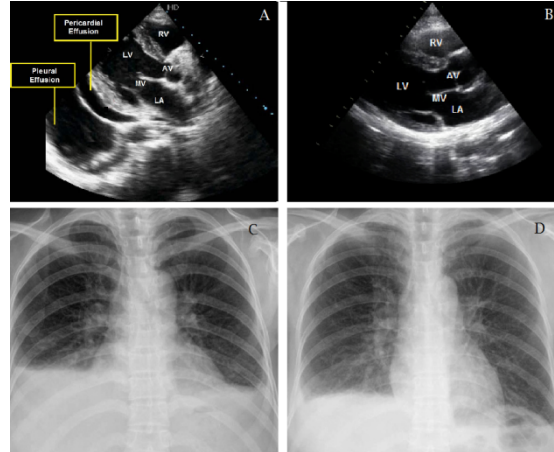


Figure-3. (A) before treatment- 2D Echo PLAX view showed pericardial and pleural effusion. (B) after treatment-2D Echo PLAX view showed clear. In figure-3 (C) before treatment- X-Ray chest PA view showed pericardial and pleural effusion. (D) after treatment- X-Ray chest PA view showed clear.

3. Discussion

Actinomyces israeli is an elongated branching gram positive bacilli, anaerobic or microaerophilic at 35 to 37 degree C temperature with slow growth on blood agar in 4-7 days or molar tooth appearance. It usually present as flora of mouth and female genital tract. In the lab, surface granules in the pus specimen, finely branching filamentous bacilli on direct gram smear and acute or chronic inflammation with surrounding granulation tissue and fibrosis on histopathological slide are diagnostic tools for actinomycosis. Apart from usual presentation, actinomyces rarely affects heart, lung and abdominal cavity rarely found . Over last three decades only a few case reports had published on actinomycosis with cardiac or pulmonary manifestation and our case unique in view of cardiopulmonary-abdominal actinomycosis.

Thoracic actinomyces commences in the lung, probably as result of aspiration of actinomyces from the mouth. Sinuses often appear on the chest wall, ribs and spine may be eroded. Primary endobronchial actinomycosis is an uncommon complication of inhaled foreign body. Also its involvement of pleura and pericardium results in pleural effusion and pericardial effusion followed by tamponade with history of shortness of breath and chest pain, muffled heart sounds and diminished breath sounds. Abdominal actinomycosis commence in the appendix or less frequently in colonic diverticulae. Pelvic actinomycosis occurs occasionally in women fitted with plastic intra-uterine contraceptive devices.

Thoracoabdominal actinomycosis is a rare and fatal condition . Ultimately it is responsible for rapid collection of pericardial, pleural or peritoneal fluid and can lead to progression of severe sepsis. All physicians should be aware about this fatal condition and its long term management by optimal drainage and prolonged uses of sensitive antibiotics like penicillin G or amoxicillin, imipenem or dorepenem, and sulfamethoxazole/trimethoprim. Initially one should treat vigorously with intravenous antibiotic therapy for 2 weeks and followed by oral antibiotics for 4 to 6 months.

4. Conclusion

Physicians should aware about this rare presentation of actinomycosis. Patients with actinomycosis require prolonged high doses of penicillin G or amoxicillin and other sensitive antibiotics for several months and drainage at an appropriate time. Early diagnosis will reduce the hospital stay or mortality in such kind of patients.

5. Acknowledgements

I would like to thanks to Dr. Maneesh Vijay MD Radiodiagnosis (AIIMS) who helped to diagnose histopathologically actinomyces israelii and special thanks to chief Editor of TAU.

6. References

6.1 Journal Article

- [1.] Garini G, Brodi C, Mazzi A, Thoracic actinomycosis with lung, mediastinal and pericardial involvement: a case report. *Recenti Prog Med* (1995);86:107–11.
- [2.] Litwin KA, Jadbabaie F, Villanueva M. Case of pleuropericardial disease caused by *Actinomyces odontolyticus* that resulted in cardiac tamponade. *Clin Infect Dis* (1999);29:219–20.
- [3.] Shinagawa N, Yamaguchi E, Takahashi T, Pulmonary actinomycosis followed by pericarditis and intractable pleuritis. *Intern Med* (2002);41:319–22.
- [4.] Wong VK, Turmezei TD, Weston VC. Actinomycosis. *BMJ*. (2011);343:d6099.
- [5.] Smego RA Jr, Foglia G. Actinomycosis. *Clin Infect Dis*. (1998);26(6): 1255–1261.
- [6.] Pulverer G, Schütt-Gerowitt H, Schaal KP. Human cervicofacial actinomycoses: microbiological data for 1997 cases. *Clin Infect Dis*. (2003);37(4):490–497.
- [7.] Fazili T, Blair D, Riddell S, Kiska D, Nagra S. *Actinomyces meyeri* infection: case report and review of the literature. *J Infect*. (2012);65(4):357–361.
- [8.] Cone LA, Leung MM, Hirschberg J. *Actinomyces odontolyticus* bacteremia. *Emerg Infect Dis*. 2003;9(12):1629–1632.
- [9.] Sabbe LJ, Van De Merwe D, Schouls L, Bergmans A, Vaneechoutte M, Vandamme P. Clinical spectrum of infections due to the newly described *Actinomyces* species *A. turicensis*, *A. radingae*, and *A. europaeus*. *J Clin Microbiol*. 1999;37(1):8–13.
- [10.] Clarridge JE 3rd, Zhang Q. Genotypic diversity of clinical *Actinomyces* species: phenotype, source, and disease correlation among genospecies. *J Clin Microbiol*. 2002;40(9):3442–3448.
- [11.] Kim SR, Jung LY, Oh IJ,. Pulmonary actinomycosis during the first decade of 21st century: cases of 94 patients. *BMC Infect Dis*. 2013;13(1):216.
- [12.] Kim TS, Han J, Koh WJ, Thoracic actinomycosis: CT features with histopathologic correlation. *AJR Am J Roentgenol*. 2006;186(1): 225–231.
- [13.] Song JU, Park HY, Jeon K, Um SW, Kwon OJ, Koh WJ. Treatment of thoracic actinomycosis: a retrospective analysis of 40 patients. *Ann Thorac Med*. 2010;5(2):80–85.
- [14.] Kolditz M, Bickhardt J, Matthiessen W, Holotiuk O, Höffken G, Koschel D. Medical management of pulmonary actinomycosis: data from 49 consecutive cases. *J Antimicrob Chemother*. 2009;63(4):839–841.
- [15.] Felz MW, Smith MR. Disseminated actinomycosis: multisystem mimicry in primary care. *South Med J*. 2003;96(3):294–299.
- [16.] Lewis R, McKenzie D, Bagg J, Dickie A. Experience with a novel selective medium for isolation of *Actinomyces* spp. from medical and dental specimens. *J Clin Microbiol*. 1995;33(6):1613–1616.
- [17.] Garner O, Mochon A, Branda J. Multi-centre evaluation of mass spectrometric identification of anaerobic bacteria using the VITEK[®] MS system. *Clin Microbiol Infect*. Epub July 4, 2013.
- [18.] Hall V, Talbot PR, Stubbs SL, Duerden BI. Identification of clinical isolates of *Actinomyces* species by amplified 16S ribosomal DNA restriction analysis. *J Clin Microbiol*. 2001;39(10):3555–3562.
- [19.] Hall V. *Actinomyces* – gathering evidence of human colonization and infection. *Anaerobe*. 2008;14:1–7.

- [20.] Smith AJ, Hall V, Thakker B, Gemmell CG. Antimicrobial susceptibility testing of Actinomyces species with 12 antimicrobial agents. *J Antimicrob Chemother.* **2005**;56(2):407–409.
- [21.] Chaudhry SI, Greenspan JS. Actinomycosis in HIV infection: a review of a rare complication. *Int J STD AIDS.* **2000**;11(6):349–355.
- [22.] Fife TD, Finegold SM, Grennan T. Pericardial actino-mycosis: case report and review. *Rev Infect – Dis* (**1991**);13:120–6.
- [23.] Garini G, Brodi C, Mazzi A, Thoracic actinomycosis with lung, mediastinal and pericardial involvement: a case report. *Recenti Prog Med* (**1995**);86:107–11.
- [24.] Litwin KA, Jadbabaie F, Villanueva M. Case of pleuropericardial disease caused by Actinomyces odontolyticus that resulted in cardiac tamponade. *Clin Infect Dis* (**1999**);29:219–20.